

## Dengue Hemorrhagic Fever Complicated with Acute Idiopathic Scrotal Edema and Polyneuropathy

Tun-Chieh Chen, Po-Liang Lu, Yen-Hsu Chen, Jih-Jin Tsai,\* and Tyen-Po Chen

*Division of Infectious Diseases, Department of Internal Medicine, Kaohsiung Medical University Hospital, Kaohsiung Medical University, Kaohsiung City, Taiwan*

**Abstract.** We report a case of an adult with dengue hemorrhagic fever who developed acute idiopathic scrotal edema and glove-and-stocking polyneuropathy. A 54-year-old man who had fever, chills, bone pain, and skin rash for 4 days was admitted. We diagnosed dengue hemorrhagic fever because of fever, gum bleeding, thrombocytopenia, and hemoconcentration, and confirmed the diagnosis by serology. The patient had scrotal and penile edema and distal limb numbness with a glove-and-stocking distribution. After supportive care, the scrotal edema and other symptoms subsided. Patients with dengue hemorrhagic fever may develop scrotal edema caused by plasma leakage.

### INTRODUCTION

Dengue fever is an acute febrile viral disease that frequently presents with high fever, headache, bone pain, and skin rash. Dengue hemorrhagic fever is characterized by the acute onset of fever, hemorrhagic diathesis, thrombocytopenia, and “plasma leakage.”<sup>1</sup> Adult acute idiopathic scrotal edema (AISE) has not been reported as a complication of dengue hemorrhagic fever. AISE, rarely reported in adults, usually affects children 4–12 years of age and is defined as a self-limited edema and erythema of the scrotum that resolves without sequelae in 1–3 days.<sup>2–4</sup> We present a case of an adult with dengue hemorrhagic fever with complications of acute scrotal edema and polyneuropathy in glove-and-stocking distribution.

### CASE REPORT

We admitted a 54-year-old man with a history of hypertension, gouty arthritis, and ankylosing spondylitis who said he suffered from dengue fever 10 years previously. He presented to the medical outpatient department of Kaohsiung Medical University Hospital, located in Kaohsiung City in southern Taiwan, on November 20, 2002 with fever, chills, headache, bone pain, and distal limb numbness in glove-and-stocking distribution for the previous 4 days. He also complained of epigastralgia, nausea, diarrhea, gum bleeding, and mild cough with blood tinged sputum. At the time of his admission, there was a large outbreak of dengue in southern Taiwan.<sup>5,6</sup>

The patient's pulse rate was 76/min, respiratory rate was 20/min, body temperature was 40.3°C, and blood pressure was 130/90 mm Hg. Examination of his head, neck, chest, and cardiovascular system revealed no abnormalities. We noted tenderness while palpating his epigastric area and a generalized maculopapular skin rash with dispersed petechiae over his lower legs. His scrotum and penis were swollen, erythematous, and had mild tenderness (Figure 1A). There was no history of trauma, voiding difficulties, or pain.

We measured the white blood cell count (3,990/mm<sup>3</sup>; normal range, 4,000–10,000/mm<sup>3</sup>), hemoglobin (14.3 g/dL; normal range, 13–17 g/dL), hematocrit (42.5%; normal range, 40%–53%), platelet count (37,000/mm<sup>3</sup>; normal range,

130,000–500,000/mm<sup>3</sup>), aspartate aminotransferase (55 U/L; normal range, 10–35 U/L), alanine aminotransferase (48 U/L; normal range, 10–40 U/L), albumin (3.95 g/dL; normal range, 3.5–5.0 g/dL), C-reactive protein (< 5 mg/L), prothrombin time (10.8 seconds; control, 10.8 seconds), and a partial thromboplastin time (46.5 seconds; control, 28.2 seconds). Urinalysis revealed > 50 red blood cells in a high-power field but no pyuria. An antibody test for mumps was negative. Serologic tests for dengue virus, performed by the Center for Disease Control in Taiwan on November 20, 2002 and December 2, 2002, showed a seroconversion of IgG and IgM antibody of dengue virus [a positive sample was defined as having a test absorbance/negative control ratio of  $\geq 2.0$ . Optic density (OD) ratios of first serum/control were 0.553/0.371 and 0.377/0.448 for IgM and IgG, respectively. OD ratios of second serum/control were 1.587/0.405 and 3.141/1.519 for IgM and IgG, respectively, by capture enzyme-linked immunosorbent assay (ELISA)].<sup>7,8</sup> Based on the criteria of the World Health Organization,<sup>1</sup> we diagnosed dengue hemorrhagic fever. The patient's chest x-ray was normal, and abdominal sonography showed fatty liver, coarse liver parenchyma, thickness of the gall bladder wall, and no ascites. Nerve conduction velocity studies of four extremities showed polyneuropathy with demyelinating and axon-degenerative types.

The patient's scrotal and penile edema progressed and eventually involved the suprapubic abdomen on 2 days after admission. The patient's fever, bone pain, gum bleeding, epigastralgia, and distal limb numbness subsided under supportive care as his platelet count declined to 14,000/mm<sup>3</sup> and hematocrit elevated to 45.5%. Urologic consultation suggested the diagnosis of AISE and recommended scrotal elevation and bed rest. His scrotal edema resolved 3 days later, along with recovery of platelet count (97,000/mm<sup>3</sup>) and hematocrit (37.4%), resulting in discharge from the hospital. The patient was totally recovered without sequelae at the follow-up visit on December 2, 2002 (Figure 1B).

### DISCUSSION

Qvist<sup>9</sup> first reported AISE in 1956. AISE accounts for 20–30% of acute scrotal disorders in young boys and is the second most common cause of acute scrotal disorders after testicular torsion. AISE predominantly affects boys between the ages of 5 and 11 years.<sup>10,11</sup> Patients with AISE are asymptomatic or complain of minimal scrotal discomfort. The

\* Address correspondence to Jih-Jin Tsai, No. 100, Tzyou 1st Road, 807 Kaohsiung City, Taiwan. E-mail: jijits@cc.kmu.edu.tw

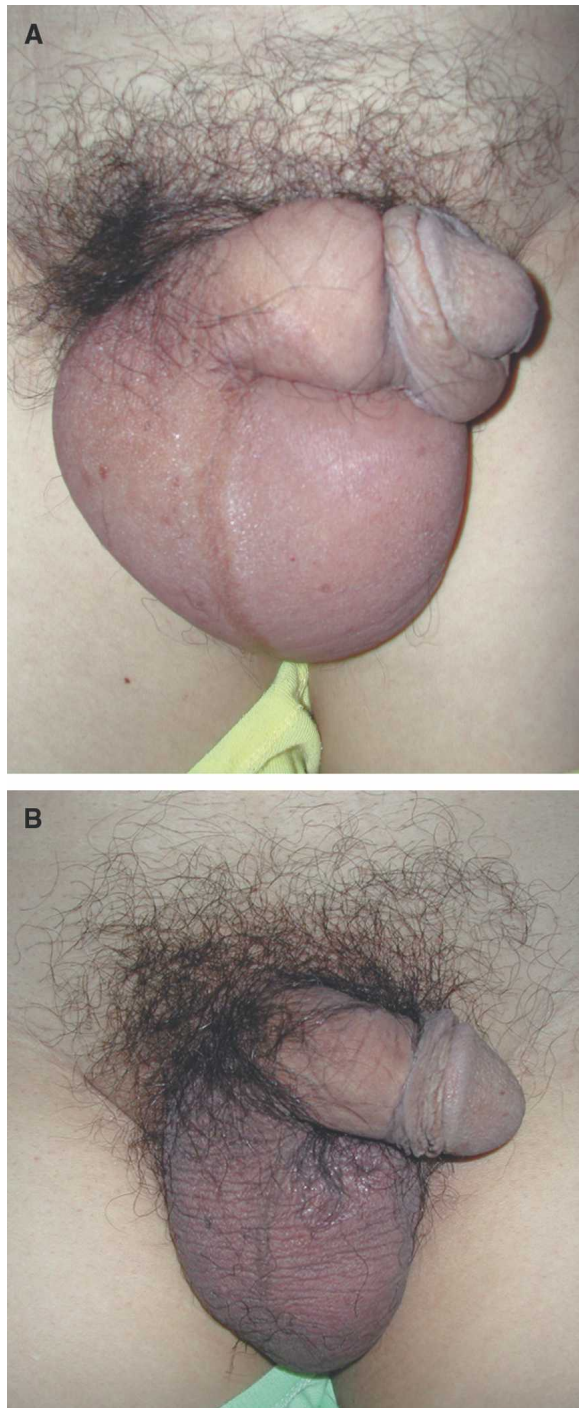


FIGURE 1. **A**, Obvious scrotal and penile edema with associated erythema in a 54-year-old patient with dengue hemorrhagic fever (November 20, 2002). **B**, The same patient on December 2, 2002, who recovered from dengue without sequelae. This figure appears in color at [www.ajtmh.org](http://www.ajtmh.org).

condition is characterized by sudden onset of subcutaneous scrotal edema, erythema, and mild scrotal pain. Typically, patients are afebrile or have a low-grade fever. With bedrest and scrotal elevation, the condition is self-limited and symptoms resolve within 6–72 hours.<sup>9–11</sup> Only six cases of AISE have been reported in adults, three of which occurred in diabetic patients with a septic foot.<sup>12–16</sup> The differential diagnosis of AISE includes epididymoorchitis, testicular or appen-

dical torsion, incarcerated inguinal hernia, and trauma that requires surgical intervention. It is important to differentiate AISE from a scrotal surgical emergency based on detailed history, physical examination, and scrotal sonography to avoid unnecessary surgical exploration.

The etiology of AISE is unknown, but several mechanisms have been proposed, including allergic reactions, trauma, insect bites, infection, urinary extravasation, and contact dermatitis.<sup>4,15</sup> The cause of AISE in this case may be caused by plasma leakage from increased vascular permeability as a consequence of dengue hemorrhagic fever. A proposed mechanism of antibody-dependent enhancement for dengue hemorrhagic fever is that numerous cytokines including tumor necrosis factor (TNF)- $\alpha$ , interleukin (IL)-2, IL-6, IL-8, and interferon (IFN)- $\gamma$  are released from endothelium, monocytes, and T cells after a secondary infection with a different serotype of dengue virus. Cross-reactive antibody, accompanied with cytokine and activated complement, results in the clearance of platelet, disruption of the coagulation system, and vascular leakage and subsequent dengue hemorrhagic fever/dengue shock syndrome.<sup>17</sup> Clinically, pleural effusion and ascites caused by plasma leakage can often be present in patients of dengue hemorrhagic fever.

The patient also suffered from transient polyneuropathy, presenting as distal limb numbness in a glove-and-stockings distribution. The result of nerve conduction velocity studies of four extremities showed polyneuropathy with both demyelinating and axon-degenerative types. Neurologic manifestations associated with dengue virus infection include encephalitis, Bell's palsy, Guillain-Barré syndrome, peroneal nerve palsy, Reye syndrome, meningoencephalomyelitis,<sup>18–20</sup> and neuromyelitis optica.<sup>21</sup> Peripheral polyneuropathy is a rare complication of dengue virus infection.<sup>22–24</sup> However, skin itching over the palms and soles, which may be a mild form of polyneuropathy, has been reported in dengue patients.<sup>5,25</sup> Neuropathologic studies in dengue patients indicated the presence of perivenous demyelinating leukoencephalopathy, possibly caused by an immuno pathogenic mechanism.<sup>26,27</sup>

In conclusion, AISE and peripheral polyneuropathy are rare manifestations of dengue hemorrhagic fever, and they are self-limiting without specific therapy. An immunologic mechanism may underlie the pathogenesis of these complications in patients with dengue.

Received August 29, 2007. Accepted for publication October 10, 2007.

Authors' addresses: Tun-Chieh Chen, Po-Liang Lu, Yen-Hsu Chen, Jih-Jin Tsai, and Tyen-Po Chen, No. 100, Tzyou 1st Road, 807 Kaohsiung City, Taiwan, Telephone: 886-7-3121101, ext. 5676, Fax: 886-7-3228547, E-mails: [tdchen.tunchieh@gmail.com](mailto:tdchen.tunchieh@gmail.com), [d830166@cc.kmu.edu.tw](mailto:d830166@cc.kmu.edu.tw), [d810070@cc.kmu.edu.tw](mailto:d810070@cc.kmu.edu.tw), [jijits@cc.kmu.edu.tw](mailto:jijits@cc.kmu.edu.tw), [880305@ms.kmu.edu.tw](mailto:880305@ms.kmu.edu.tw).

## REFERENCES

1. World Health Organization, 1997. Clinical diagnosis. World Health Organization, eds. *Dengue Hemorrhagic Fever: Diagnosis, Treatment, Prevention and Control*. Second edition. Geneva: World Health Organization, 12–23.
2. Weinberger LN, Zirwas MJ, English JC III, 2006. A diagnostic algorithm for male genital oedema. *J Eur Acad Dermatol Venerol* 21: 156–162.
3. Galejs LE, Kass EJ, 1999. Diagnosis and treatment of the acute scrotum. *Am Fam Physician* 59: 817–824.

4. Kass EJ, Lundak B, 1997. The acute scrotum. *Pediatr Clin North Am* 44: 1251–1266.
5. Lee MS, Hwang KP, Chen TC, Lu PL, Chen TP, 2006. Clinical characteristics of dengue and dengue hemorrhagic fever in a medical center of southern Taiwan during the 2002 epidemic. *J Microbiol Immunol Infect* 39: 121–129.
6. Kuo MC, Chang JM, Lu PL, Chiu YW, Chen HC, Hwang SJ, 2007. Difficulty in diagnosis and treatment of dengue hemorrhagic fever in patients with chronic renal failure: report of three cases of mortality. *Am J Trop Med Hyg* 76: 752–756.
7. Shu PY, Chen LK, Chang SF, Yueh YY, Chow L, Chien LJ, Chin C, Lin TH, Huang JH, 2003. Comparison of capture immunoglobulin M (IgM) and IgG enzyme-linked immunosorbent assay (ELISA) and nonstructural protein NS1 serotype-specific IgG ELISA for differentiation of primary and secondary dengue virus infections. *Clin Diagn Lab Immunol* 10: 622–630.
8. Innis BL, Nisalak A, Nimmannitya S, Kusalerdchariya S, Chongswasdi V, Suntayakorn S, Puttisri P, Hoke CH, 1989. An enzyme-linked immunosorbent assay to characterize dengue infections where dengue and Japanese encephalitis co-circulate. *Am J Trop Med Hyg* 40: 418–427.
9. Qvist O, 1956. Swelling of the scrotum in infants and children, and non-specific epididymitis. A study of 158 cases. *Acta Chir Scand* 110: 417–421.
10. Nicholas JL, Morgan A, Zachary RB, 1970. Idiopathic edema of scrotum in young boys. *Surgery* 67: 847–850.
11. Najmaldin A, Burge DM, 1987. Acute idiopathic scrotal oedema: incidence, manifestations and aetiology. *Br J Surg* 74: 634–635.
12. Brandes SB, Chelsky MJ, Hanno PM, 1994. Adult acute idiopathic scrotal edema. *Urology* 44: 602–605.
13. Sasso F, Nucci G, Palmiotto F, Giurtacchini M, Alchini E, 1990. Acute idiopathic scrotal oedema: rare disorder or difficult diagnosis. *In Urol Nephrol* 22: 475–478.
14. Kinn AC, Eld J, 2003. Acute erysipelas oedema in the scrotum. *Scand J Urol Nephrol* 37: 366–367.
15. Shah J, Qureshi I, Ellis BW, 2004. Acute idiopathic scrotal oedema in an adult: a case report. *Int J Clin Pract* 58: 1168–1169.
16. Fahal AH, Suliman SH, Sharfi AR, El Mahadi EMA, 1993. Acute idiopathic scrotal oedema in association with diabetic septic foot. *Diabetes Res Clin Pract* 21: 197–200.
17. Fink J, Gu F, Vasudevan SG, 2006. Role of T cells, cytokines and antibody in dengue fever and dengue hemorrhagic fever. *Rev Med Virol* 16: 263–275.
18. Patey O, Ollivaud L, Breuil J, Lafaix C, 1993. Unusual neurologic manifestations occurring during dengue fever infection. *Am J Trop Med Hyg* 48: 793–802.
19. Chen TC, Perng DS, Tsai JJ, Lu PL, Chen TP, 2004. Dengue hemorrhagic fever complicated with acute pancreatitis and seizure. *J Formos Med Assoc* 103: 865–868.
20. Palma-da Cunha-Matta A, Soares-Moreno SA, Cardoso-de Almeida A, Aquilera-de Freitas V, Carod-Artal FJ, 2004. Neurological complications arising from dengue virus infection. *Rev Neurol* 39: 233–237.
21. Miranda de Sousa A, Puccioni-Sohler M, Dias Borges A, Fernandes Adorno L, Papais Alvarenga M, Papais Alvarenga RM, 2006. Post-dengue neuromyelitis optica: case report of a Japanese-descendent Brazilian child. *J Infect Chemother* 12: 396–398.
22. Acevedo J, Casanova MF, Antonini AC, Morales H, 1982. Acute polyneuritis associated with dengue. *Lancet* 1: 1357.
23. Paul C, Dupont B, Pialoux G, 1990. Acute polyradiculoneuritis secondary to dengue. *Presse Med* 19: 1503.
24. Sainte-Foie S, Niel L, Moreau JP, Ast-Ravallec, Chippaux A, 1993. A case of polyradiculoneuritis associated with dengue in a patient native to French Guiana. *Bull Soc Pathol Exot* 86: 117–118.
25. Hwang KP, Su SC, Chiang CH, 1989. Clinical observations of dengue fever among children. *Kaohsiung J Med Sci* 5: 50–57.
26. Chimeli L, Hahn MD, Netto MB, Ramos RG, Dias M, Gray F, 1990. Dengue: neuropathological findings in 5 fatal cases from Brazil. *Clin Neuropathol* 9: 157–162.
27. Bhoopat L, Bhamarapavati N, Attasiri C, Yoksarn S, Chaiwun B, Khunamornpong S, Sirisanthana V, 1996. Immunohistochemical characterization of a new monoclonal antibody reactive with dengue virus-infected cells in frozen tissue using immunoperoxidase technique. *Asian Pac J Allergy Immunol* 14: 107–113.